

# Tooth Extractions From Live-captured White-tailed Deer

## *Introduction*

---

Age is an important attribute of an animal, and knowledge of it is critical to understanding animal ecology. For example, Clutton-Brock et al.'s (1982) comprehensive study of red deer (*Cervus elaphus*) documented age effects on fat reserves, mortality rate, fecundity, offspring weights, offspring survival, maternal behavior, and social behavior for females. In males, age was related to dominance and reproductive success. However, such analyses often require a high level of accuracy because yearly variation can profoundly influence physiological processes and ecological dynamics. The accuracy rate of aging known-age white-tailed deer (*Odocoileus virginianus*) by tooth eruption and wear (Severinghaus 1949) was only 43%, but it increased to 85% using *cementum annuli* counts of incisors (Hamlin et al. 2000). Thus, ages determined by eruption and wear are not very useful in examining age effects in white-tailed deer ecology. Surprisingly, examination of 1990-1999 *Journal of Wildlife Management* publications on odocoileine deer revealed that in only 1 of 17 studies involving live-captures of deer were canines or incisors extracted for aging of *cementum annuli*. In the 16 other studies, a minimum of 1,163 adult deer were captured. The actual number of adults must have been much larger because age class was not reported in 8 of the studies.

Why would researchers not collect the most accurate age data from a study animal if the opportunity presents itself and the information is potentially relevant? Some studies examined aspects of deer ecology unlikely to be influenced by animal age, and some occurred in southern latitudes where *cementum* aging appears unreliable. However, not all of the studies fit that profile and 4 of those examined mortality and survival, phenomena directly influenced by age. Three of these aged deer by tooth replacement and wear (Severinghaus 1949), apparently accepting less accurate age data than that potentially available from *cementum annuli* (Erickson et al. 1970, Gilbert and Stolt 1970). Possibly the researchers considered canine extraction too difficult and time-consuming, or perhaps they were unaware of the technique. My search for information on tooth extraction in ungulates in 3 bibliographic sources produced only Bergerud and Russell's (1966) paper in the *Journal of Wildlife Management*, a veterinary dentistry book (Wiggs and Lobprise 1997), and 12 papers in the veterinary literature, most only tangential to the topic. Thus, it would not be surprising if wildlife biologists were unfamiliar with tooth extraction from live animals. Herein, I describe incisor and canine extraction from live-captured white-tailed deer and outline a quick, simple procedure that enhances the results and interpretations from long-term studies.

---

[Return to Contents](#)

[Next Section](#) -- Methods

---

# Tooth Extractions From Live-captured White-tailed Deer

## *Acknowledgments*

---

This study was supported by the United States Fish and Wildlife Service, the United States Geological Survey, and the Special Projects Foundation. I thank L. D. Mech for administering the project and critiquing the manuscript. I also acknowledge numerous volunteer wildlife technicians who assisted in live-capture and handling of deer. This research was conducted under the auspices of the Pautuxent Wildlife Research Center, United States Fish and Wildlife Service, Animal Care and Use Committee, study plan 2700202.

**Michael E. Nelson** is a wildlife research biologist with the United States Geological Survey. he has studied deer ecology and deer-wolf interactions in northeastern Minnesota for 26 years. Mike received his B.S., M.S., and Ph.D. degrees from the University of Minnesota.



---

[Previous Section](#) -- Results and Discussion

[Return to Contents](#)

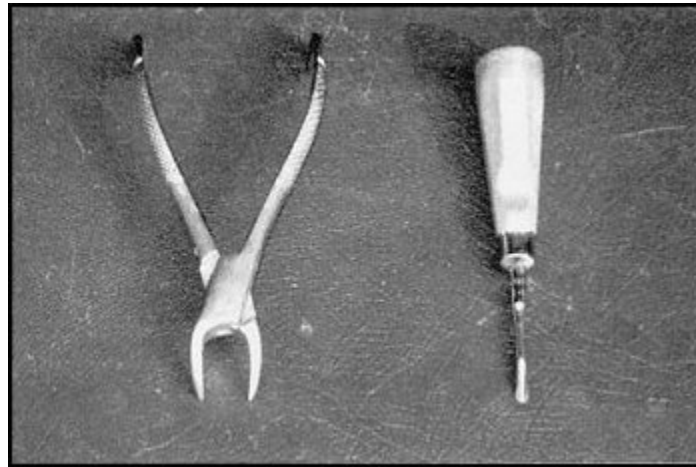
[Next Section](#) -- Literature Cited

---

# Tooth Extractions From Live-captured White-tailed Deer

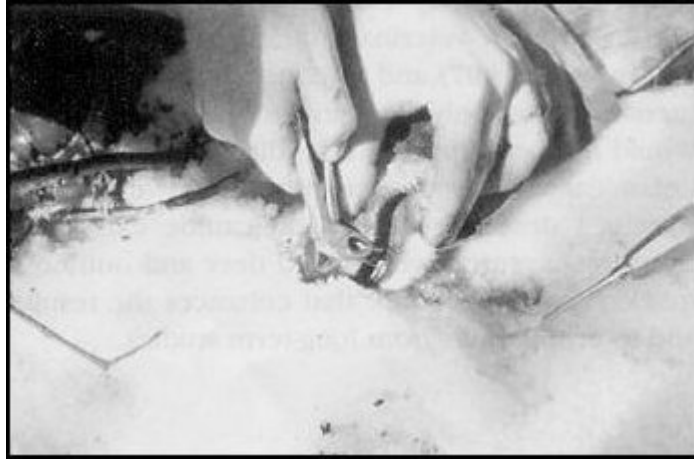## *Methods*

The necessary tools for tooth extraction are a dental elevator (#9), used to separate the gum from the tooth, and a dental forceps (#13), for pulling the tooth from its socket (Bergerud and Russell 1966). I immobilized deer with xylazine hydrochloride and ketamine hydrochloride (Kreeger 1996) for removal from Clover traps or rocket-nets. I kept deer anesthetized throughout the processing and administered penicillin before reversing the xylazine with yohimbine hydrochloride (Mech et al. 1985). I generally extracted a tooth about 20 minutes after immobilization.



Dental forceps and elevator used to extract incisorform teeth.

To begin an extraction, I place the deer's head in a secure position and select one of the canines for extraction. Bergerud and Russell (1966) suggested holding the head on the operator's knee. I prefer to have the head against the ground and then kneel to perform the extraction. While holding the jaw steady and parting the lips with one hand, I hold the elevator in the other hand with my index finger near the tip. This finger position maximizes control over the elevator, which prevents slippage into adjacent gum tissue and bone (Wiggs and Lobprise 1997). By gently pushing the elevator between the tooth and gum while rotating it around the tooth, the ligaments holding the tooth to the bone are weakened. Any bleeding is minor and ceases soon after the extraction. I then make prying movements to further loosen the ligaments. By placing the elevator between the canine and the adjacent incisor and then prying sideways, the tooth loosens rapidly.



Extracting a canine from an anaesthetized deer by means of a dental elevator (lying on right) and forceps.

Deeper penetration of the elevator and further pressure then nearly complete the process. The objective is to have a very loose, wobbly tooth that can be rotated easily with one's fingers. Finally, I place the dental forceps over the tooth so that the forceps tips are below the gum line. Slow, even, upward pressure then pulls the tooth free from the socket. Sometimes a little additional rotation may be needed. However, the use of much force often results in a broken tooth, indicating that the loosening by the elevator was inadequate. This is a common mistake when learning the procedure. The elevator should be used to almost complete the extraction. If the canine is broken during extraction, I next select the other canine for removal. I have extracted the adjacent incisor (I3) on the rare occasion when first-time operators broke both canines. The procedure, once learned, routinely takes <5 minutes.

---

[Previous Section](#) -- Introduction

[Return to Contents](#)

[Next Section](#) -- Results and Discussion

---

**Northern Prairie Wildlife Research Center**

# Tooth Extractions From Live-captured White-tailed Deer

## *Results and Discussion*

---

During 1977-1999, assistants and I collected canines from 343 live-captured white-tailed deer. We recaptured 26 of the animals an average of 2 weeks later and noted no healing problems associated with previous tooth extraction. We recaptured an additional 29 deer a mean of 3 years after extraction; all appeared to have normal gum tissue at the extraction site, and the adjacent teeth seemed normal. More than 90% of the deer with canines extracted survived and were radiotracked for >1 additional year. Wolves (*Canis lupus*) killed those deer that died earlier, and there was no behavioral or anatomical evidence suggesting that tooth extraction predisposed deer to predation. Thus, the trauma of tooth extraction was superficial and temporary. Because of the lateral position and diminutive size of the canine, it requires only minor surgery for extraction, which aids in rapid healing. Furthermore, the size and morphometry of the canine suggests it has only a minimal role in biting function and therefore its contribution to survival is probably minor.

Although it is not necessary, I have occasionally used fresh wolf-killed or road-killed deer to teach tooth extraction to assistants before they handle live deer. Certainly, if both canines and an I3 are broken in a first extraction, the trainee should perfect the technique on a recently killed deer before the next tooth extraction on a live deer.

I did not attempt tooth extraction without anesthesia; however, tooth extraction using a local anesthetic has been successful on physically restrained elk (*Cervus elaphus*) (L. D. Mech, personal communication) and presumably would be similarly successful on restrained deer.

---

[Previous Section](#) -- Methods

[Return to Contents](#)

[Next Section](#) -- Acknowledgments

---

# Tooth Extractions From Live-captured White-tailed Deer

## *Literature Cited*

---

- BERGERUD, A. T., and H. L. RUSSELL. 1966. Extraction of incisors of Newfoundland caribou. *Journal of Wildlife Management* 30: 842-843.
- CLUTTON-BROCK, T. H., F. E. GUINNESS, and S. D. ALBON. 1982. Red deer: Behavior and ecology of two sexes. University of Chicago, Chicago, Illinois, USA.
- ERICKSON, J. A., A. E. ANDERSON, D. E. MEDIN, and D. C. BOWDEN. 1970. Estimating ages of mule deer—an evaluation of technique accuracy. *Journal of Wildlife Management* 34:523-531.
- GILBERT, F. F., and S. L. STOLT. 1970. Variability in aging Maine white-tailed deer by tooth-wear characteristics. *Journal of Wildlife Management* 34:532-535.
- HAMLIN, K. L., D. F. PAC, C. A. SIME, R. M. DESIMONE, and G. L. DUSEK. 2000. Evaluating the accuracy of ages obtained by two methods for Montana ungulates. *Journal of Wildlife Management* 64:441-449.
- KREEGER, T. J. 1996. Handbook of wildlife chemical immobilization. International Wildlife Veterinary Services, Incorporated, Laramie, Wyoming, USA.
- MECH, L. D., G. D. DELGIUDICE, P. D. KARNS, and U. S. SEAL. 1985. Yohimbine as an antagonist to xylazine-ketamine immobilization of white-tailed deer. *Journal of Wildlife Diseases* 21: 405-410.
- SEVERINGHAUS, C. W. 1949. Tooth development and wear as criteria of age in white-tailed deer. *Journal of Wildlife Management* 13:195-216.
- WIGGS, R. B., and H. B. LOBPRISE. 1997. *Veterinary dentistry: principles and practice*. Lippincott-Raven, Philadelphia, Pennsylvania, USA.

---

[Previous Section](#) -- Acknowledgments

[Return to Contents](#)

---